



Anatomical Variations in the Brachial Artery, Extensor Carpi Radialis Longus and Musculocutaneous Nerve in Adult Male Sudanese Cadavers

Mohammed Abdelsalam Ahmed Abdelmotalab^{1*}

¹*Department of Human and Clinical Anatomy, Riyadh International College, Sudan.*

Author's contribution

The sole author designed, analyzed and interpreted and prepared the manuscript.

Article Information

DOI: 10.9734/AJRIMPS/2018/42617

Editor(s):

(1) Dr. Raghvendra Vijay Ramdasi, Professor, Department of Neurosurgery, Jaslok Hospital & Research Centre, Mumbai, India.

Reviewers:

(1) Isaac Echoru, Kampala International University, Uganda.
(2) Anthony Ocaya, Gulu University, Uganda.

Complete Peer review History: <http://www.sciencedomain.org/review-history/25400>

Original Research Article

Received 20th April 2018
Accepted 24th June 2018
Published 4th July 2018

ABSTRACT

Knowledge of different variations is important for the clinicians and other medical disciplines for the diagnostic, interventional and surgical procedures. The aim of this study is to report any unusual observations of anatomical structures during the dissection of properly embalmed three male cadavers at the department of human anatomy at National University Faculty of Medicine from 1st July 2015 to 5th May 2016. Cadaver (1) about 70 years old male was showed anatomical variations in musculocutaneous nerve formation. Cadaver (2) about 60 years old male shows that extensor carpi radialis longus inserted by two tendons. Cadaver (3) about 55 years was showed the high division of brachial artery into radial and ulnar arteries at the upper end of the arm. No additional variation was observed. The unusual observations should be reported due to their greater clinical significance.

Keywords: Dissection; observations; variations; cadavers and brachial artery.

*Corresponding author: E-mail: Salam_ahamed@yahoo.com;

1. INTRODUCTION

The musculocutaneous nerve gives a twig to the shoulder joint and a branch to coracobrachialis, then it proceeds between the two conjoined parts of coracobrachialis. After that the musculocutaneous nerve descends down between biceps and brachialis and innervates the two muscles, it was accompanied by many branches of the brachial artery and tributaries of the brachial veins. At the lateral border of the biceps tendon continues as the lateral cutaneous nerve of the forearm. The musculocutaneous is the nerve of the flexor compartment of the arm [1].

The musculocutaneous nerve passes under the coracobrachialis muscle and then continues until its first branch to the biceps brachialis muscle. Just after this, it supplied another two branches, the lateral cutaneous nerve of the forearm and a branch to the brachialis muscle and then it joined the median nerve approximately at the midpoint of the arm and the median nerve [2].

The MCN supply the coracobrachialis muscle and then it ran downwards and medially joined the median nerve after 3.5 cm from its formation. The other two muscles of the front of the arm, biceps brachii and brachialis were supplied by the median nerve after it received the musculocutaneous nerve. The lateral cutaneous nerve of forearm also emerged from median nerve [3]. The musculocutaneous nerve gave out a communicating branch to join the median nerve just proximal to the entrance of the musculocutaneous nerve into coracobrachialis. Subsequent courses of both the median and musculocutaneous nerves were found to be normal. The right side of the brachial plexus was also dissected and examined, and the course and distribution of the musculocutaneous and median nerves were found to be without any communication [4].

The extensor carpi radialis longus (ECRL) is a fusiform muscle, is partly overlapped by the brachioradialis, with which it often blends. As it passes distally, posterior to the brachioradialis, its tendon is crossed by the abductor pollicis longus and extensor pollicis brevis. It originated from the lateral supraepicondylar ridge of humerus and inserted in the dorsal aspect of base of 2nd metacarpal it innervated by radial nerve (C6, C7). The extensor carpi radialis longus muscle extend and abduct the hand at the wrist joint [5].

An additional belly of muscle having common origin with extensor carpi radialis longus muscle was found on the medial side of ECRL muscle, having a long tendon which started from the small belly of the muscle, it ended by getting inserted into the upper and medial aspect of dorsal surface of base of second metacarpal bone [6].

The extensor carpi radialis longus was giving two tendons in the second compartment of extensor retinaculum before its insertion while passing deep to the abductor pollicis longus, while the Extensor carpi radialis brevis was absent [7]. A rare variation of the extensor carpi radialis longus muscle was observed in a 49-year-old male cadaver during routine dissections. An accessory slip of the extensor carpi radialis longus muscle with a short belly part arising from the ulnar side and a long, thin tendon extending to the radial side of the wrist crossing over the main tendon was found inserted in the dorsal and lateral side of first metatarsal bone [8].

The brachial artery continues on from the axillary and ends at the level of the neck of the radius by dividing into the radial and ulnar arteries. It is superficial (immediately below the deep fascia) along its whole course, except where it is crossed, at the level of the middle of the humerus, by the median nerve which passes superficially from its lateral to the medial side, sometime the nerve crosses deep to the artery. Fairly frequently the artery divides into its two terminal branches in the upper arm. The branches of the artery are; the profunda brachii, superior ulnar collateral, nutrient to the humerus and inferior ulnar collateral [9].

A higher division of brachial artery was observed, with the artery dividing in the arm just below to teres major muscle into its terminal branches, the radial artery laterally and ulnar artery medially, the artery had passed superficial to the median nerve before its division [10].

In a 45 year, male cadaver unusual variation of right brachial artery branching was observed. The brachial artery was showed a high division in to radial and ulnar arteries in the upper third of arm, then radial artery passed through the apex of the fossa, lying medial to the median nerve, while the ulnar artery cross deep to the deep head of the pronator teres muscle [11]. Gourassas 2003 presented a case-report of a patient with a failed radial coronary angiography approach, due to the abnormality in the high

division of brachial artery [12]. Normal brachial artery was found in 42 specimens accounting for 84%. Variations presents in 8 specimens (16%), (10%) presented with bifurcation of brachial artery into radial, ulnar and radial recurrent arteries, (2%) presented with double profunda brachii artery, (2%) showed high origin of radial artery and (2%) presented with high division of brachial artery in the proximal third of arm (2%) [13].

2. MATERIALS AND METHODS

The present study was conducted on three properly embalmed male cadavers were completely dissected at the department of human anatomy at National University Faculty of Medicine from 1st July 2015 to 5th May 2016. The skin, superficial fascia, deep fascia and muscles were separated using a scalpel and forceps and the extensor carpi radialis longus, musculocutaneous nerve and brachial artery with their relation to the surrounding structures were examined.

2.1 Observational Results

During the dissection of cadaver (1) variation in musculocutaneous nerve was encountered in the left upper limb. The musculocutaneous nerve was originated from the lateral cord of brachial plexuses normally then it was pierced the coracobrachialis muscle and innervates it and then passing down between the brachialis and biceps brachii for one cm where it was joined the median nerve on its lateral side at the upper part of the arm, they became as one nerve after 4cm from the formation of the median nerve, the lateral root of median relatively thin than usual. After 2 cm from receiving the musculocutaneous nerve the median nerve give arises to the lateral cutaneous nerve of the forearm. The MSC nerve innervates the biceps brachii from its lateral side at the site of junction with median nerve Fig. 1. The musculocutaneous nerve in the right upper limb has normal course and distributions.

The left upper limb of cadaver (2) was showing anatomical variation in the extensor carpi radialis longus gave additional tendon, which they passed together deep to abductor pollicis longus and extensor pollicis brevis, the main tendon entered into the second compartment of extensor retinaculum where it was lateral to additional tendon and extensor carpi radialis brevis tendon to appear in the dorsum. Finally it was ended by getting inserted into the upper and medial aspect

of dorsal surface of base of second metacarpal bone. The additional tendon pass deep to the main tendon close to the extensor carpi radialis brevis tendon on its lateral side they was inserted on the dorsal aspect of base of third metacarpal bone Figs. 2 and 3. On the right upper limb does not show any variations.

Another important variation was observed during the dissection of the cadaver (3) Fig. 4. the brachial artery of the right upper limb showed a high division into radial and ulnar arteries at the upper end of the arm, in the lower arm the radial artery cross superficial to the median nerve and has normal course in the forearm. The ulnar artery pass deep to the median then on the medial side in the cubital fossa they pass together between the heads pronator teres, the ulnar artery has normal course in the forearm. On the left side the brachial artery was normal.

3. DISCUSSION

Anatomical variations in the extensor carpi radialis longus musculocutaneous nerve and the brachial artery were revealed by the present study. Sergio, et al. 2016 mentioned that the musculocutaneous nerve supplies the coracobrachialis muscle and then continues until it gives branches to the biceps brachii and then brachialis muscle and lateral cutaneous nerve of the forearm. After that it join the median nerve at the midpoint of the arm [2]. In this study the left musculocutaneous nerve of cadaver (1) Fig. 1 pierce the coracobrachialis muscle supplying it and joining the median after 1 cm of exit out of the muscle, then MSC nerve innervates the biceps brachii from its lateral side at the site of junction with median nerve, after 2 cm from receiving the musculocutaneous nerve the median nerve give arises to the lateral cutaneous nerve of the forearm.

The musculocutaneous nerve gave out a communicating branch to join the median nerve just proximal to the entrance of the musculocutaneous nerve into coracobrachialis [4]. In comparison to the current study finding the musculocutaneous nerve join the median nerve after 4 cm from its formation, and there is no communication before that.

The communications between the musculocutaneous and median nerves classified into following five types: type I, there is no communication between the MN and the MCN, in type II, the fibers of the lateral root of the MN



Fig. 1. Cadaver (1) shows a variation that the left musculocutaneous nerve (MCN) has join the median nerve (MN) at the upper part of the arm, after the MCN piercing the coracobrachialis (CBM) under cover of the biceps brachii (BM). The lateral cutaneous nerve of the forearm (LCNF) present as a branch from median nerve

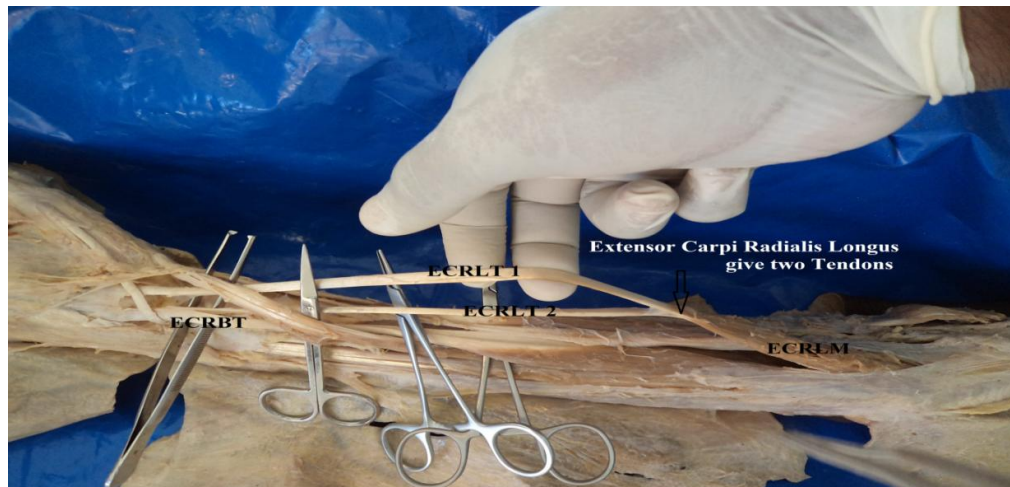

Fig. 2. Cadaver (2) shows that the extensor carpi radialis longus has two tendons, the main tendon (ECRLT 1) inserted into the base of the second metacarpal bone, the additional tendon (ECRLT 2) inserted in common with extensor carpi radialis brevis (ECRB) in the base of the second metacarpal bone

pass through the MCN nerve and join the MN in the middle of the arm, whereas in type III, the lateral root fibers of the MN pass along the MCN and after some distance, leave it to form the lateral root of the MN. In type IV, the MCN fibers join the lateral root of the MN and after some distance, the MCN originates from the MN. In type V, the MCN is completely absent and its

fibers pass through the lateral root and fibers to the muscles supplied by MCN branch out directly from the MN [14]. The current study variation of left musculocutaneous nerve in Fig. 1 does not similar to any of the Le Minor categories types, but the lateral root of left median nerve were observed small than usual and this may or may not give an indication of traveling of some

of its fibers through the musculocutaneous nerve.

Phalguni Srimani, et al. 2014 reported that the extensor carpi radialis longus muscle has an additional belly of muscle having common origin having a long tendon inserted into the upper and medial aspect of the dorsal surface of the base of second metacarpal bone [6]. In the present study observations the left extensor carpi radialis main tendon inserted in the base of the second metacarpal bone while the additional tendon ass deep to the main on to be inserted into the base of the third metacarpal bone in common with extensor carpi radialis brevis muscle as present in Figs. 2. and 3. The extensor carpi radialis longus Jang & Lee 2003 mentioned that a thin

long tendon Jang & Lee 2003 mentioned that a thin long tendon arising from the ulnar side of extensor carpi radialis longus muscle extending to the radial side of the wrist crossing over the main tendon was found inserted in the dorum and lateral side of first metatarsal bone [8]. This study found that the additional tendon of extensor carpi radialis longus muscle inserted in the base of the third metatarsal bone.

A higher division of brachial artery had been reported by K. Smitha 2013, the artery dividing in the arm just distal to teres major muscle [10]. This study was showed same observation in right upper limb of cadaver (3) Fig. 4. The brachial divided in to radial and ulnar arteries in upper third of arm at the the lower border of the teres

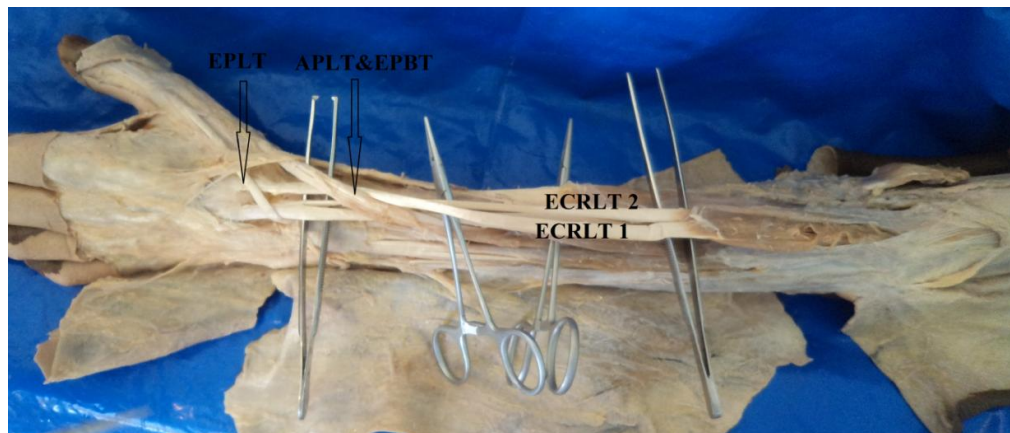


Fig. 3. Cadaver (2) shows that the tendons of extensor carpi radialis longus muscle on the dorsum of the forearm and wrist joint passes deep to the abductor pollicis longus, (APLT) extensor pollicis brevis tendon (EPBT) and extensor pollicis longus (EPLT) tendons

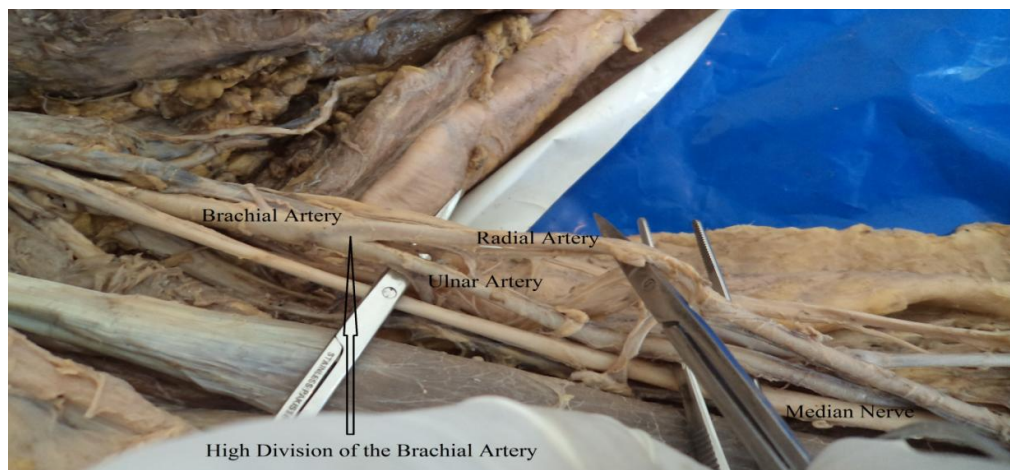


Fig. 4. Cadaver (3) shows a high division of left brachial artery is into ulnar and radial arteries at the upper part of the arm

major muscle, then radial artery passed through the apex of the fossa, lying medial to median nerve, while the ulnar artery cross deep to the deep head of the pronator teres muscle [11]. It similar to the finding of the present study, their course in the forearm is normal and there is no such variation were observed. Brachial artery variations can have both morphological and clinical significance.

4. CONCLUSION

Knowledge of unusual variations is important in medicine, it may cause misinterpretation of angiographic images. Accidental puncture of superficially placed arteries may occur while attempting vena puncture. Abnormal origin of the radial artery may cause the failure of the radial approach of the coronary angiography and in the reconstructive surgery of the upper limb. Lesions of communicating nerves may give rise to difficulty diagnosis in clinical neurophysiology. So any unusual observations during the dissection of cadavers should be reported because it is essential not only to anatomists, but also to radiologists, orthopedists, vascular and plastic surgeons.

CONSENT

It is not applicable.

ETHICAL APPROVAL

As per international standard or university standard, written approval of Ethics committee has been collected and preserved by the author(s).

COMPETING INTERESTS

Author has declared that no competing interests exist.

REFERENCES

1. McMinn RMH. Abdomen part 15, lasts anatomy regional and applied. 9th Ed. Churchill livingstone.199;781-82.
2. Sergio R, Cristiane R, et al. Rare anatomical variation of the musculocutaneous nerve – case report. Revbrasortop J. 2016;51(3):366–369.
3. Sachdeva K, Singla R. Communication between median and musculocutaneous nerve. J Morphol Sci. 2011;28(4):246-249.
4. Anyanwu G, Agu A, et al. Contribution of musculocutaneous nerve in the formation of median nerve. JECA. 2013;2(12).
5. Moore K. Clinically oriented anatomy, 5th edition. Lippincott Williams & Wilkins. Toronto, Toronto, Ontario, Canada. 2006; 808.
6. Phalguni S, Rudradev M, et al. Unilateral variation of extensor carpi radialis longus muscle: A case report. Int J Anat Var. 2014;7:115–117.
7. Prakash R, Gajendra S. Multiple variations of extensor muscles of forearm in relation to the radial nerve: A case report and review. Int J Morphol. 2008;26(2):447-449.
8. Jang C, Jae L. Accessory head of the extensor carpi radialis longus muscle merging with extensor carpi radialis brevis muscle. G M J. 2003;14(4):197-199.
9. Harold E. The abdomen and pelvis, clinical anatomy, applied anatomy for students and junior doctors. 11th Ed, Blackwell Publishing Ltd. 2006;201-202.
10. Smitha K. J of Evol of Med and Dent Sci. 2013;2(8):938.
11. Chandrika T, et al. J Med Dent Sci. High Division and Variation in Brachial Artery Branching Pattern. 2013;3(6):68-70.
12. Gourassas J. Anomalous origin of right radial artery as a cause of radial approach failure of coronary angiography. J Cardiol. 2003;44:226-229.
13. Uma Shivanal, Trinesh MS. A study of variations in brachial artery and its branching pattern. Int. J Res Med Sci. 2015;3(6):1392-1396.
14. Le minor JM. A rare variant of median and musculocutaneous nerves in man. Arch Anat. Histol Embryol. 1990;73:33-42.

© 2018 Abdelmotalab; This is an Open Access article distributed under the terms of the Creative Commons Attribution License (<http://creativecommons.org/licenses/by/4.0>), which permits unrestricted use, distribution, and reproduction in any medium, provided the original work is properly cited.

Peer-review history:

The peer review history for this paper can be accessed here:
<http://www.sciencedomain.org/review-history/25400>