



# Protective Properties of *Citrullus lanatus* on Carbon Tetrachloride Induced Liver Damage in Rats

Abiodun Humphrey Adebayo<sup>1\*</sup>, Omolara Faith Yakubu<sup>1</sup>  
and Tolulope Mariam Balogun<sup>1</sup>

<sup>1</sup>Biochemistry and Molecular Biology Unit, Department of Biological Sciences, College of Science and Technology, Covenant University, PMB 1023, Canaan land, Ota, Ogun State, Nigeria.

## Authors' contributions

This work was carried out in collaboration between all authors. Author AHA designed the study, performed the statistical analysis, wrote the protocol, and wrote the first draft of the manuscript. Author OFY carried out the experimental and proof read the manuscript and Author TMB also did the experimental, literature searches, and managed the analyses of the study. 'All authors read and approved the final manuscript.'

Original Research Article

Received 22<sup>nd</sup> February 2014  
Accepted 9<sup>th</sup> April 2014  
Published 4<sup>th</sup> June 2014

## ABSTRACT

**Aim:** This study was conducted to investigate the effects of the leaf extract of *Citrullus lanatus* on carbon tetrachloride (CCl<sub>4</sub>) induced liver damage in rats.

**Methodology:** Hepatoprotective study was conducted using five groups (A-E) of six male rats per group. Groups A and B served as the control groups and were respectively administered with distilled water and CCl<sub>4</sub> in olive oil while groups C, D and E were administered respectively with 500, 1,000 and 1,500mg/kg body weight of the ethanolic leaf extract of *C. lanatus* for 7 days. Animals were subsequently anaesthetized, blood samples were collected for alanine amino transferase (ALT), aspartate amino transferase (AST), alkaline phosphatase (ALP), total bilirubin, total protein and albumin assays; liver organ was isolated and processed for biochemical and histopathological studies.

**Results:** There were significant increases (P=0.05) in the serum levels of ALT and AST both in the plasma and liver homogenate in the group treated with CCl<sub>4</sub> as compared to negative control group; while in the extract treated group, there was a decrease in the levels of the aminotransferases. Histopathological studies showed severe portal

\*Corresponding author: Email: [abiodun.adebayo@covenantuniversity.edu.ng](mailto:abiodun.adebayo@covenantuniversity.edu.ng);

congestion and necrosis of hepatocytes in the group treated with CCl<sub>4</sub> while the groups administered with the extract treated group showed a moderate venous congestion with absence of necrosis.

**Conclusion:** These results highlight the ability of the leaf extract of *C. lanatus* to ameliorate damage in the liver of albino rats.

**Keywords:** *Citrullus lanatus*; *Cucurbitaceae*; carbon tetrachloride; hepatoprotective property; histopathological studies.

## 1. INTRODUCTION

The liver plays a pivotal role in the metabolism of toxic substances that enter the body. Carbon tetrachloride (CCl<sub>4</sub>) is one of these toxic substances; its toxicity begins with the change in endoplasmic reticulum, which results in the loss of metabolic enzymes located in the intracellular structures. CCl<sub>4</sub> is biotransformed by the cytochrome P<sub>450</sub> system to produce the toxic metabolite trichloromethyl free radicals, which in turn covalently binds to cell membranes and organelles to elicit lipid peroxidation [1]. Medicinal plants are plants which contain substances that could be used for therapeutic purposes or which are precursors for the synthesis of useful drugs [2]. For decades, the screening of medicinal plant materials for their therapeutic values has continued to represent potential sources of new effective medicines. *Citrullus lanatus* (Water melon) is a member of the cucurbit family (*Cucurbitaceae*). Water melon refers to both fruit and the plant of a vine-like (scrambler and trailer) plant that is widely cultivated for its edible fruits, which are also an important source of water in arid regions of Africa. It is an annual climbing or trailing herb, with hairy stem up to 10m long, the leaf blades are up to about 20x20cm, more or less hairy, usually deeply 3-5 lobed, the central lobe being the largest. The lobes themselves are further divided. Leaf stalks (petioles) are up to about 19cm long, more or less hairy [3]. This flowering plant produces a special type of fruit known as a pepo, a berry which has a thick rind (exocarp) and fleshy center (mesocarp and endocarp); pepos are derived from an inferior ovary, and are characteristic of the *Cucurbitaceae*. The watermelon fruit, loosely considered a type of melon (although not in the genus *Cucumis*), has a smooth exterior rind (green, yellow and sometimes white) and a juicy, sweet usually red, but sometimes orange, yellow or pink interior flesh [4]. It is also commonly used to make a variety of salads, most notably fruit salad [5]. The ripe fruits are edible and largely used for making confectionary. Its nutritive values are also useful to the human health. Fruit is used in cooling, strengthening, aphrodisiac, astringent to the bowels, indigestible, expectorant, diuretic, and stomachic, purifies the blood, allays thirst, cures biliousness, good for sore eyes, scabies and itches and as brain tonic to the brain [6]. The following phytochemicals: saponins, phenols, anthraquinones, terpenoids, alkaloids, cardiac glycosides, tannins have been reported in the seeds and whole fruits of *C. lanatus* [7]. Citrullin and lycopene are the most commonly isolated phytochemicals and they have been implicated in the management of cardio vascular diseases and cancer [8]. It is noteworthy to mention that most literature reviews revealed reports on the seed extract of *C. lanatus* but the leaf has not been generally given consideration. Moreover, the search for potent natural therapy against the various degrees of liver pathology led to this study and hence the present study was conducted to explore the protective effect of the leave extract of *C. lanatus* against CCl<sub>4</sub> liver induced damage in albino rats.

## 2. MATERIALS AND METHODS

### 2.1 Plant Material

The leaves of *Citrullus lanatus* were obtained from a farmland at Owode, Ogun State on 16<sup>th</sup> December, 2010 and the plant was authenticated at the Department of Pharmacognosy, University of Lagos, Lagos, Nigeria.

### 2.2 Preparation of Extracts

The procedure described by Adebayo et al. [9] was adopted. The leaves of *C. lanatus* were picked and dried under room temperature for about three days and then smoothly ground using a dry blender and thus prepared for extraction. The powdered leaves of *Citrullus lanatus* (588g) were soaked in 7L of 70% ethanol for four days, after which the extract was filtered with filter paper and a cotton wool. It was further concentrated at 50°C using a rotary evaporator, RE300 and further concentrated using water bath at 48°C.

### 2.3 Experimental Animals

Thirty male albino rats with an average weight of 150g which were used for this study were obtained from the Animal House of the Department of Biochemistry, University of Agriculture, Abeokuta, Nigeria. The animals were kept at a maintained temperature and fed with standard feed (grower's mash). The experimental animals were handled and used in accordance with the international guide for the care and use of laboratory animals of the National Institute of Health [10]. They were kept in standard laboratory conditions under natural light-dark cycle. The rats also had access to clean drinking water and variable factors such as light, temperature and humidity were maintained.

### 2.4 Experimental Design

Thirty (30) male albino wistar rats were used for the study. The method as described by Adebayo et al. [9] was adopted. The rats were divided into five groups, each group consisting of six animals. The first two groups (A and B) served as negative and positive controls respectively while groups C, D, and E served as the treatment groups. Group A served as normal group and was given only vehicle (distilled water, 1ml/kg body weight) for seven (7) days. Group B, positive control and was served with vehicle for the first four days and vehicle + CCl<sub>4</sub> (50% solution of CCl<sub>4</sub> in olive oil, 2ml/kg body weight) on the 5<sup>th</sup>, 6<sup>th</sup>, and 7<sup>th</sup> day. Groups C, D, and E were served with 500, 1,000, and 1,500mg/kg body weight of distilled water and ethanolic leaf extract for the first four days and distilled water+ethanolic extract+CCl<sub>4</sub> on the last three days. They were all administered according to their body weight and after seven days, the rats were subjected to overnight fasting and they were anaesthetized in diethylether and subsequently sacrificed the following day.

### 2.5 Blood Collection and Preparation of Sample

At the end of the experimental period, venous blood was collected from the experimental animals by cardiac puncture using syringe for the determination of serum enzyme levels and other biochemical analyses. The serum was prepared by centrifuging the heparinized blood samples at 3000rpm for 15min [11] and collected by pipetting. The animals were also quickly dissected and the liver removed. The liver was suspended in ice-cold solution and

homogenized. The homogenates were kept frozen overnight to ensure maximum release of the enzymes [12].

## 2.6 Analysis of Biochemical Parameters

Commercial test kits obtained from Randox Laboratories, United Kingdom were used for all biochemical parameters measured. Standard methods were used to estimate aspartate amino transferase (AST), alanine aminotransferase (ALT) [13], alkaline phosphatase (ALP) [14], total protein [15], albumin [16] and total bilirubin [17].

## 2.7 Histopathological Analysis

Small pieces of liver fixed in 10% buffered neutral formalin were processed for embedding in paraffin [18]. Sections of 5-6 $\mu$ m thickness were stained with hematoxylin and eosin, examined for histopathological changes under a compound microscope.

## 2.8 Statistical Analysis

The difference among experimental and control groups were determined using SPSS for Windows XP software programme (version 13.0). Group comparison was done using the analysis of variance (ANOVA) test. Significant difference between control and experimental were assessed by least significant difference (LSD). All data were expressed as mean $\pm$ SEM; *P*-values less than 0.05 were considered to be significant.

## 3. RESULTS

There was no significant difference (*P* > 0.05) in the weight of the organs of rats between the groups treated with the extract of *C. lanatus* groups when compared with control groups (Table 1).

**Table 1. Effects of *Citrullus lanatus* on the weight of some organs of CCl<sub>4</sub> induced hepatotoxicity in rats**

Parameters	A	B	C	D	E
LUNGS (g)	1.84 $\pm$ 0.04	1.79 $\pm$ 0.35	2.07 $\pm$ 0.07	1.79 $\pm$ 0.09	1.77 $\pm$ 0.35
LIVER (g)	7.49 $\pm$ 0.31	8.68 $\pm$ 0.45	8.76 $\pm$ 0.44	8.61 $\pm$ 0.50	8.08 $\pm$ 0.59
BRAIN (g)	2.70 $\pm$ 0.07	2.19 $\pm$ 0.23	2.84 $\pm$ 0.54	2.77 $\pm$ 0.03	2.78 $\pm$ 0.03
HEART (g)	1.63 $\pm$ 0.05	1.58 $\pm$ 0.071	1.53 $\pm$ 0.13	1.65 $\pm$ 0.19	1.72 $\pm$ 0.21
SPLEEN (g)	1.89 $\pm$ 0.44	1.55 $\pm$ 0.074	1.89 $\pm$ 0.11	1.83 $\pm$ 0.11	1.56 $\pm$ 0.07
KIDNEY (g)	1.86 $\pm$ 0.02	2.03 $\pm$ 0.02	1.93 $\pm$ 0.59	1.98 $\pm$ 0.11	1.90 $\pm$ 0.07

Values represent mean $\pm$ SEM of 6 replicates. \* *P*=0.05 was taken as statistically significant value compared to the control. A=negative control; B=CCl<sub>4</sub> induced group; C=CCl<sub>4</sub>+500mg/kgbw extract; D=CCl<sub>4</sub>+1000 mg/kg bw extract; E=CCl<sub>4</sub>+1500mg/kgbw extract

Administration of CCl<sub>4</sub> resulted in significant (*P*=0.05) increase in both the serum and homogenate levels of ALT and AST when compared with the control group (Tables 2 and 3). This is an indication of liver damage caused by CCl<sub>4</sub>. AST and ALT levels in the CCl<sub>4</sub> treated group from the serum were elevated by 347 and 24.7% respectively (Table 2).

**Table 2. Effect of *Citrullus lanatus* on the serum liver function parameters of CCl<sub>4</sub> induced hepatotoxicity in rats**

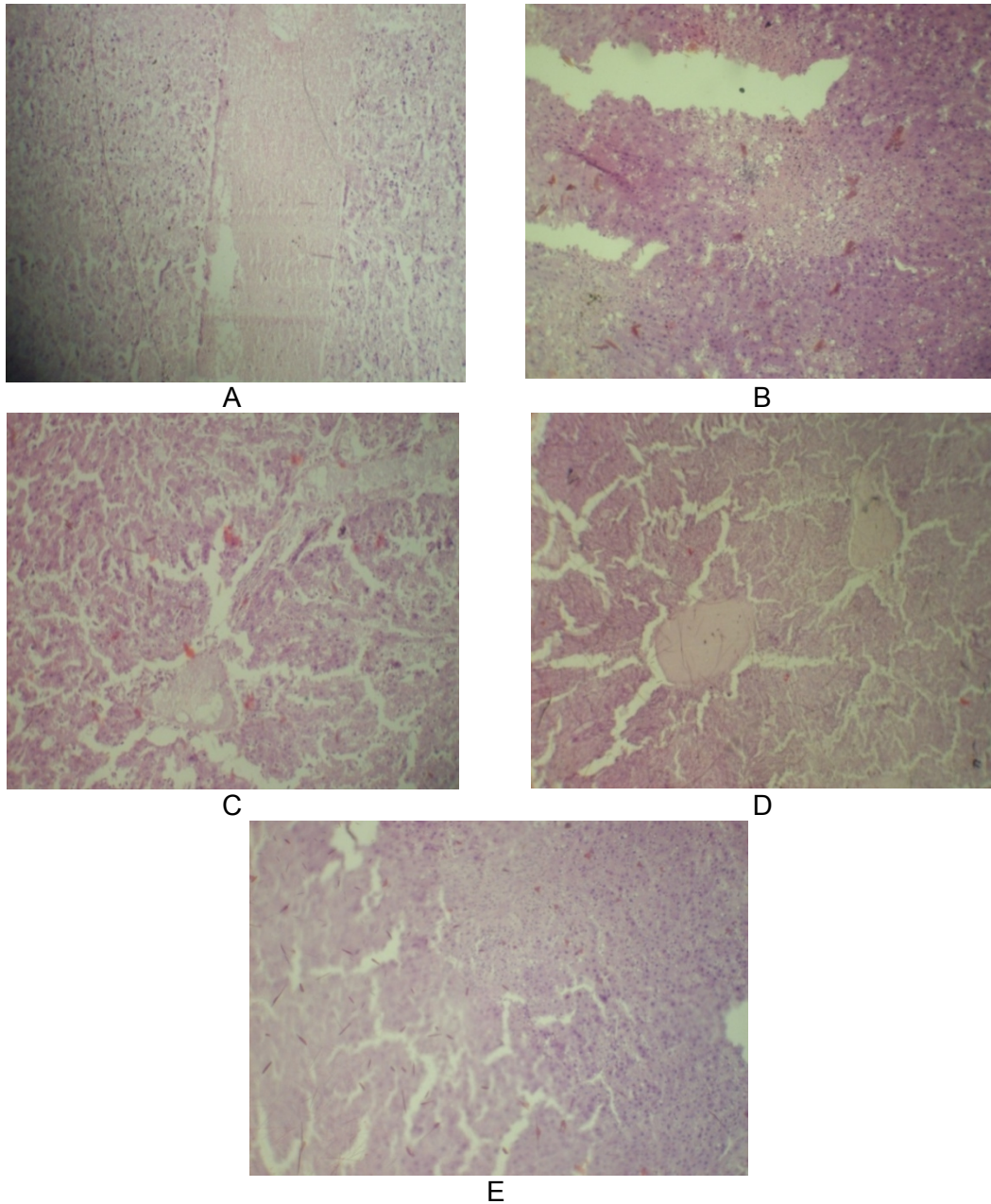
Parameters	A	B	C	D	E
AST(U/L)	15.40±1.75	52.00±9.76	16.50±3.71 <sup>b</sup>	18.00±6.56 <sup>b</sup>	18.75±3.01 <sup>b</sup>
ALT(U/L)	66.67±2.68	89.33±1.93	86.80±4.19 <sup>a</sup>	80.00±7.59 <sup>a</sup>	89.00±3.46 <sup>a</sup>
ALP(U/L)	207.00±16.39	214.05±20.86	253.18±32.62	208.84± 41.08	238.28±50.30
Albumin (g/dL)	2.87±0.07	3.50±0.22	3.17±0.13	2.96±0.08 <sup>b</sup>	2.97±0.08 <sup>b</sup>
T. Protein (g/dL)	6.22±0.19	5.70±0.23	6.82±0.32 <sup>b</sup>	5.95±0.42	6.07±0.25
T. Bilirubin (g/dL)	0.33±0.28	0.19±0.08	0.17±0.04	0.14±0.04	0.22±0.06

Values represent mean±SEM of 6 replicates. <sup>a</sup>P=0.05 when compared to negative control. <sup>b</sup>P=0.05 when compared to positive control. A=negative control; B=CCl<sub>4</sub> induced group; C=CCl<sub>4</sub>+500mg/kg bw extract; D=CCl<sub>4</sub>+1000mg/kg bw extract; E=CCl<sub>4</sub>+1500mg/kg bw extract

**Table 3. Effect of *C. lanatus* on liver function parameters in liver homogenate of CCl<sub>4</sub> induced hepatotoxicity in rats**

Parameters	A	B	C	D	E
AST (U/L)	593.33±43.33	710.0±69.50	626.0±65.77	491.67±78.93 <sup>b</sup>	292.50±27.80 <sup>ab</sup>
ALT (U/L)	701.67±16.21	870.0±31.94	824.0±41.30 <sup>a</sup>	690.0±44.35 <sup>b</sup>	835.0±16.58 <sup>a</sup>
ALP (U/L)	80.96±12.34	236.44±40.35	48.15±15.51 <sup>b</sup>	86.20±22.67 <sup>b</sup>	209.45±41.23 <sup>a</sup>
Albumin (g/dL)	0.53±0.05	0.50±0.04	0.54±0.12	0.42±0.11	0.50±0.06
T. Protein (g/dL)	1.29±0.37	0.69±0.16	0.97±0.43	0.24±0.07 <sup>a</sup>	0.27±0.11 <sup>a</sup>
T. Bilirubin (g/dL)	0.48±0.30	0.30±0.09	0.64±0.24	1.26±0.74	0.15±0.51

Values represent mean±SEM of 6 replicates. <sup>a</sup>P=0.05 when compared to negative control. <sup>b</sup>P=0.05 when compared to positive control. A=negative control; B=CCl<sub>4</sub> induced group; C=CCl<sub>4</sub>+500mg/kgbw extract; D=CCl<sub>4</sub>+1000mg/kgbw extract; E=CCl<sub>4</sub>+1500mg/kgbw



**Fig. 1. Photomicrograph of (a): Normal liver architecture of albino Wistar rat, H&Ex160 (b) liver of rat treated with CCl<sub>4</sub> showing severe portal congestion, severe vacuolar degeneration and necrosis of hepatocytes, mild cellular infiltration by mononuclear cells, H&Ex160 (c): Liver of rat treated with CCl<sub>4</sub> and 500mg/kg bw of extract of *C. lanatus* showing severe diffuse vacuolar degeneration of hepatocytes, with diffuse cellular infiltration by mononuclear cells, H&Ex160 (d): Liver of rat treated with CCl<sub>4</sub> and 1000mg/kg bw of *C. lanatus* extract showing marked central venous congestion, H&Ex160. (e): Liver of rat treated with CCl<sub>4</sub> and 1500mg/kgbw of *C. lanatus* extract showing moderate portal and central venous congestion, H&Ex160**

Similarly, the activities of AST and ALT were also increased in the homogenates by 16.5 and 24.1% respectively (Table 3). The result as reported in (Table 2) indicated that the animals treated with the extract after CCl<sub>4</sub> induction showed a significant ( $P=0.05$ ) decrease in the activity of AST (representing 215, 189 and 177% for groups C, D and E respectively). While ALT level was reduced by 3.5 and 11% in groups C and D respectively. Total protein and albumin levels were significantly ( $P=0.05$ ) different from CCl<sub>4</sub> control group when compared with the negative control group, these effects were however reversed upon treatment with the extract of *C. lanatus*. Similarly, in (Table 3), the elevated AST level in the CCl<sub>4</sub> treated group was reversed upon treatment with the extract across the groups (13.4, 44.4, and 142.7% respectively). Moreover, ALT activity which was previously increased in the CCl<sub>4</sub> treated group was also reversed by the extract across the groups (5.5, 26.9, 4.2% respectively) (Table 3). Histological examination of the liver in the CCl<sub>4</sub> treated group showed severe portal congestion, severe vascular degeneration and necrosis of hepatocytes. Treatment with the extract of *C. lanatus* showed mild to moderate portal and central venous congestion which indicates protection from hepatotoxicant (Fig. 1).

#### 4. DISCUSSION

Medicinal plants are significant sources of hepatoprotective drugs whose efficacy depends largely on their ability to either reduce harmful effects or maintain normal hepatic physiological mechanism, which may have been altered by a hepatotoxin [19]. Carbon tetrachloride (CCl<sub>4</sub>) is a halogenated alkane classified as a potential human carcinogen that increases the frequency of liver tumors in experimental animals [20]. The primary effects in humans are on the liver, kidney and central nervous systems. It has been proved to be one of the most powerful hepatotoxins capable of forming trichloromethyl and trichloromethylperoxyl radicals [21]. Intoxification by CCl<sub>4</sub> and its metabolites (CCl<sub>3</sub> radicals) resulted in significant hepatic damage. For instance, CCl<sub>4</sub> is activated by a metabolic enzyme (cytochrome P<sub>450</sub> dependent mixed oxidase) in the endoplasmic reticulum to form trichloromethyl radicals, which induce peroxidation of unsaturated fatty acids of cell membranes leading to membrane damage and leakage of sensitive markers of hepatocellular injury such as serum AST and ALT [22]. The results of biochemical parameters revealed an elevation of enzyme levels in CCl<sub>4</sub>-treated group, indicating that CCl<sub>4</sub> induces damage to the liver. In particular, increased ALT levels are indicative of liver damage [9]. ALT is a cytoplasmic enzyme present and specific to the liver and is emptied into the blood stream once cellular membrane is damaged [23], hence it is considered as a specific indicator of liver status [24,25]. Our result showed significant increase in ALT and AST levels in the CCl<sub>4</sub>-treated group both in the serum and liver homogenate. The elevated levels of these liver marker enzymes are indications of cell membrane damage in the hepatocytes leading to loss of functional integrity of the liver [26-28]. The results of the enzyme levels obtained in this study (Table 2) is in agreement with work of Abdel-Hamid [29] and Venukumar et al. [30] who reported the elevation in the levels of hepatic enzymes in rats administered with CCl<sub>4</sub>. Alkaline phosphatase (ALP) is the most widely used test to detect blockage in the biliary system. It is found in the bile and liver and leaks into the blood stream in a similar manner to that of ALT and AST [31]. CCl<sub>4</sub>-treated group showed elevated ALP activity which was also significantly lowered by the extract. A high level of ALP indicates intra-hepatic cholestasis and obstructive jaundice [9]. There was an appreciable reduction of plasma bilirubin in rats treated with higher doses of the extract; this implies the absence of jaundice and the efficacy of the extract to activate a normal functional liver status. This corroborates with the findings of Adebayo et al. [32] where the ethanol extract of *C. albidum* was not only found to significantly reduce the elevated level of plasma bilirubin in CCl<sub>4</sub> liver

induced rats, but the activities of the AST and ALT hepatic enzymes indicating hepatoprotection against the toxicant.

The biochemical study from our findings is in tandem with the work carried out to examine the protective effects of caffeic acids and quercetin on chemical induced hepatotoxicity in rodents, where similar dose of caffeic acids and quercetin was found to reverse serum rise of ALT and AST enzyme activities in CCl<sub>4</sub> induced hepatic damage [33]. Similarly, the hepatoprotective activity of the extract of *A. indicum* on experimental CCl<sub>4</sub> induced liver damaged rats was studied. Administration of CCl<sub>4</sub> significantly elevated the serum levels of ALT, AST, ALP and bilirubin. However, pretreatment with *A. indicum* aqueous extract showed a dose-dependent protection against the injurious effects of CCl<sub>4</sub> that may result from the interference with cytochrome P<sub>450</sub> [34]. The observed significant increase in total protein in serum of rats treated with low dose may have been due to proteins mass increase as a result of CCl<sub>4</sub> induction or possible increased in intracellular enzymes and elevated globulin due to enhanced antibody secretion in response to the toxicant but this was sharply brought to normalcy as the doses were increased. The significant decrease in albumin as compared to the CCl<sub>4</sub> group may be due to the binding of the endogenous albumin with bilirubin, it could also be due to possible protein degeneration. Albumin is produced entirely in the liver and is of great importance in regulating the flow of water between the plasma and tissue fluid by its effect on colloid osmotic pressure. A drop in serum albumin level is usually the result of reduced protein synthesis by the liver or induced protein loss through the gut or the kidney. Other possible causes of decrease in albumin level may include mal-absorption and increased protein need secondary to infection [35,36] (Halsted and Halsted, 1981; Cheesbrough, 1998). Histological examinations also validated the biochemical investigations; there was moderate portal and central venous congestion in the treated groups especially in the groups treated with the highest dose of the extract when compared with the CCl<sub>4</sub> treated groups which showed a severe vacuolar degeneration and necrosis of hepatocytes. Certain phytochemicals like flavonoids, triterpenoids and steroids have been reported to have protective effect on the liver as a result of their antioxidant properties [37]. Some novel flavonoid glycosides from the leaf extract of *C. lanatus* have been isolated in our laboratory, although it is yet to be published. The hepatoprotective property of this plant may be due to the presence of flavonoid in their individual state or as a result of the combined effects of these phytochemicals. The exact phytochemical responsible for the hepatoprotective property needs further investigation.

## 5. CONCLUSION

In conclusion therefore, the leave extract of *C. lanatus* has been established to reverse the toxic effect of CCl<sub>4</sub> in the liver of albino Wistar rats and could consequently serve as potential therapy for the management of some liver disorders.

## CONSENT

Not applicable.

## ETHICAL APPROVAL

All authors hereby declare that "Principles of laboratory animal care" (NIH publication No. 85-23, revised 1985) were followed, as well as specific national laws where applicable. All experiments have been examined and approved by the appropriate ethics committee.



## COMPETING INTERESTS

Authors have declared that no competing interests exist.

## REFERENCES

1. Recknagel O, Glende A, Dolak A, Waller C. Mechanism of carbon tetrachloride toxicity. *Pharmacol. Toxicol.* 1989;43:139-154.
2. Abolaji OA, Adebayo AH, Odesanmi OS. Nutritional qualities of three medicinal plant parts (*Xylopia aethiopica*, *Blighia sapida* and *Parinari polyandra*) commonly used by pregnant women in the western part of Nigeria. *Pak. J. Nutr.* 2007;6:665-668.
3. Maynard D, Maynard DN. Cucumbers, melons and watermelons. In: *The Cambridge World History of Food*, ed. K. F. Kiple & K. C. Ornelas, Cambridge University Press, Cambridge, UK; 2000.
4. Daniel Z, Maria H. Domestication of plants in the old world. 3rd edition, Oxford University Press, UK. 2000;193.
5. Dane L, Liu J. Diversity and origin of cultivated and citron type watermelon (*Citrullus lanatus*). *Genet Res Crop Evol.* 2007;54:1255-1265.
6. Rahman AHMM, Anisuzzaman M, Ferdous A, Rafiul AKM, Naderuzzaman ATM. Study of nutritive value and medicinal uses of cultivated cucurbits. *J. Appl. Sci. Res.*, 2008;4:555-558.
7. Oseni OA, Okoye VI. Studies of Phytochemical and Antioxidant properties of the fruit of watermelon (*Citrullus lanatus*). (Thunb.). *J. Pharm. Biomed. Sci.* 2013;27:508-514.
8. Senthil K, Aranganathan S, Nalini N. Evidence of oxidative stress in the circulation of ovarian cancer patients. *Clin. Chim. Acta.* 2004;339:27-32.
9. Adebayo AH, Tan NH, Akindahunsi AA, Zeng GZ, Zhang YM. Anticancer and antiradical scavenging activity of *Ageratum conyzoides* L. (Asteraceae). *Phcog. Mag.* 2010;6:62-66.
10. National Institute of Health (NIH). Guide for the Care and Use of Laboratory Animals. US. Department of Health Education and Welfare. NIH Publication No. 1985;85-123.
11. Ogbu SI, Okechukwu EI. The effect of storage temperature prior to separation on plasma and serum potassium. *J. Med. Lab. Sci.* 2001;10:1-4.
12. Ngaha EO, Akanji MA, Madusuolunmo MA. Studies on correlation between chloroquine-induced tissue damage and serum enzyme changes in rat. *Experimentia* 1989;45:143-146.
13. Reitman S, Frankel S. In vitro determination of transaminase activity in serum. *J. Clin. Path.* 1957;28:56-60.
14. Tietz W, Rinker D, Shaw M. International Federation of Clinical Chemistry (IFCC) methods for the measurement of catalytic concentration of enzymes. Part 5. IFCC method for alkaline phosphatase (orthophosphoric-monoester phosphohydrolase, alkaline optimum, EC 3.1.3.1). *J. Clin. Chem. Clin. Biochem.* 1983;21:731-748.
15. Weichselbaum TE. Biuret method of serum total protein estimation. *Am. J. Clin. Path.* 1946;16:40.
16. Doumas BT, Watson WA, Biggs HG. Albumin standards and the measurement of serum albumin with bromocresol green. *Clin. Chem. Acta.* 1971;31:87-96.
17. Doumas BT, Perry BW, Sasse EA, Straumfjord JV. Standardization in bilirubin assays: Evaluation of selected methods and stability of bilirubin solutions. *Clinical Chemistry.* 1973;19:984-993.

18. Aliyu R, Adebayo AH, Gatsing D, Garba IH. The effects of ethanolic leaf extract of *Commiphora africana* (Burseraceae) on rat liver and kidney functions. J. Pharmacol. Toxicol. 2007;2:373-379.
19. Hukkeri VI, Jaiprakash B, Lavhale MS, Karadi RV, Kuppast IJ. Hepatoprotective activity of *Ailanthus excelsa* Roxb. leaf extract on experimental liver damage in rats. Pharmacognosy. 2003;11:1-2.
20. Anonymous. Toxicological review of carbon tetrachloride. In Support of Summary Information on the Integrated Risk Information System (IRIS). US Environmental Protection Agency. 2010; 300:4-6. Accessed 16 July 2013. Available: [www.epa.gov/iris](http://www.epa.gov/iris).
21. Weber LWD, Boll M, Stampfl A. Hepatotoxicity and mechanism of action of haloalkanes: Carbon tetrachloride as a toxicological model. Crit. Rev. Toxicol. 2003;33:105-136.
22. De Groot H, Nell T. The critical role of low steady state oxygen partial pressures in haloalkane free-radical mediated lipid peroxidation. Biochem. Pharmacol. 1986;35:15-19.
23. Lin SC, Chung TC, Ueng TH, Linn YH, Hsu SH, Chiang CL, Lin CC. The hepatoprotective effects of *Solnum alatum* moench on acetaminophen induced hepatotoxicity in mice. Am. J. Clin. Med. 2000;28:105-114.
24. Predes FS, Pinto da Matta SL, Monteiro JC and Toledo de Oliveira T. Investigation of Liver Tissue and Biochemical Parameters of Adult Wistar Rats treated with *Arctium lappa* L. Brazilian Archives of Biology and Technology. 2009;52:335-40.
25. Parmar MY, Shah PA, Gao J, Gandhi TR. Hepatoprotection through regulation of voltage dependent anion channel expression by *Amomum subulatum* Roxb seeds extract. Ind. J. Pharmacol. 2011;43:671-675.
26. Dufour DR. Laboratory guidelines for screening, diagnosis and monitoring of hepatic injury. Nat. Acad. Clin. Biochem. 2000;12.
27. Obi FO, Usenu LA, Osayande JO. Prevention of carbon tetrachloride induced hepatotoxicity in the rat by *Hibiscus rosainensis* anthocyanin extract administered in ethanol. Toxicol. 1998;131:93-98.
28. Wegwu MO, Ayalogu EO, Sue OJ. Anti-oxidant protective effects of *Cassia alata* in rats exposed to carbon tetrachloride. J. Appl. Sci. Environ. Mgt. 2005;9:77-80.
29. Abdel-Hamid NM. Diphenyl dimethyl bicarboxylate as an effective treatment for chemical treatment for chemical-induced fatty liver in rats. Afr. J. Biomed. Res. 2006;9:77-81.
30. Venukumar MR, Latha MS. Hepatoprotective effect of the methanolic extract of *Curculigo orchioides* in CCl<sub>4</sub>-treated male rats. Int J. Pharmacol. 2009;5:45-50.
31. Schumann G, Klauke R, Canalias F, Bossert-Reuther S, Franck PF, Gella FJ, Jørgensen PJ, Kang D, Lessinger JM, Panteghini M, Ceriotti F. IFCC primary reference procedures for the measurement of catalytic activity concentrations of enzymes at 37 °C. Part 9: Reference procedure for the measurement of catalytic concentration of alkaline phosphatase. Clin. Chem. Lab. Med. 2011;49:1439-1446.
32. Adebayo AH, Abolaji OA, Kela R, Oluremi SO, Owolabi OO, Ogungbe OA. Hepatoprotective activity of *Chrysophyllum albidum* against carbon tetrachloride induced hepatic damage in rats. Can. J. Pure and Appl. Sci. 2011;3:1597-1602.
33. Janbaz KH, Saeed SA, Gilani AH. Studies on the protective effect of Caffeic acid and quercetin on chemical-induced hepatotoxicity in rodent. Phytomedicine. 2004;11:424-30.
34. Porchezian E, Ansari. Hepatoprotective activity of *Abutilon indicum* on experimental liver damage in rats. Phytomedicine. 2005;12:62-64.

35. Halsted JA, Halsted CH. The laboratory in clinical medicine: Interpretation and application, 2nd edition. WB. Saunders Company, Philadelphia. 1991;281-283.
36. Cheesbrough M. District laboratory practice in tropical countries, part 1. Cambridge University press, Cambridge. 1998;355-358.
37. Gupta AK, Misra N. Hepatoprotective activity of aqueous ethanolic extract of *Chamomile capitula* in paracetamol intoxicated albino rats. N. Am. J. Pharmacol. Toxicol. 2006;1:17-20.

---

© 2014 Adebayo et al.; This is an Open Access article distributed under the terms of the Creative Commons Attribution License (<http://creativecommons.org/licenses/by/3.0>), which permits unrestricted use, distribution, and reproduction in any medium, provided the original work is properly cited.

*Peer-review history:*

The peer review history for this paper can be accessed here:  
<http://www.sciencedomain.org/review-history.php?iid=519&id=13&aid=4807>