



Penetrating Scrotal Injury: Two Unusual Case Reports in Children and Brief Review of Literature

**Emmanuel Owusu Ofori^{1*}, Baba Alhaji Bin Alhassan¹, Samuel Essoun²,
Alvin Asante-Asamani³ and Patrick Maison⁴**

¹Department of Surgery, Cape Coast Teaching Hospital, Ghana.

²Department of Surgery, Korle Bu Teaching Hospital, Ghana.

³Department of Surgery, Cape Coast Teaching Hospital, Ghana.

⁴Department of Surgery, School of Medical Sciences, University of Cape Coast, Ghana.

Authors' contributions

This work was carried out in collaboration among all authors. Author EOO did the entire write up of the manuscript. Authors SE and AAA put the case notes together. Author BABA managed the literature searches. Author PM proofread and edited the entire manuscript. All authors read and approved the final manuscript.

Article Information

DOI: 10.9734/JAMMR/2020/v32i930480

Editor(s):

(1) Syed Faisal Zaidi, King Saud Bin Abdulaziz University-HS, Saudi Arabia.

Reviewers:

(1) Marzia Cottini, Sacco University Hospital, Italy.

(2) Avinash Kumar, AIIMS, India.

Complete Peer review History: <http://www.sdiarticle4.com/review-history/57863>

Case Report

Received 05 April 2020

Accepted 11 June 2020

Published 22 June 2020

ABSTRACT

Introduction: Scrotal trauma is a rare surgical emergency that accounts for less than 1% of all traumatic injuries. They are more prevalent in 15-40 years age group. Blunt scrotal trauma contributes to about 80% of all scrotal injuries whilst penetrating scrotal injuries constitute the remaining 20%. Penetrating scrotal injuries are however, more rare in children but can result from bicycle handlebars, falls with impalement, and animal bites.

Case Reports: We did a retrospective review of our records over a 7-year period for penetrating scrotal injuries and report two (2) cases involving 13-year old and 14-year old males who sustained injuries from a tree branch and an iron rod respectively after falling from heights.

Discussion: Penetrating scrotal trauma can present with complex injury patterns involving the testes and other surrounding structures, and all invariably need urgent scrotal exploration.

*Corresponding author: E-mail: emma2ofori@yahoo.co.uk;

Consequently, both of our cases had immediate surgical exploration with conservative debridement of non-viable tissue and surprisingly both were spared any testicular injury.
Conclusion: Penetrating scrotal trauma may spare the testis and the scrotal contents despite the gravity of the injury.

Keywords: Scrotal trauma; blunt trauma; penetrating trauma; injuries; scrotal exploration.

1. INTRODUCTION

Scrotal trauma is rare surgical emergency that accounts for less than 1% of all traumatic injuries, largely because of the safe anatomical location and mobility of the scrotum [1]. These injuries are predominantly more prevalent in 15-40 years age group [2]. There are various mechanisms of scrotal trauma, of which blunt trauma is the commonest form. Blunt scrotal trauma contributes to about 80% of all scrotal injuries [1]. In children, most blunt scrotal trauma occurs most commonly among 6 to 12 year old boys with typical mechanisms including falls or kicks during sports and injuries from bicycle or motor vehicle collisions [3,4]. Penetrating trauma also contributes to about 20% of scrotal injuries [1]. However, penetrating scrotal injuries are rare in children but can occur from bicycle handlebars, falls with impalement and animal bites [5,6]. In addition, among adolescents and young adults, gunshot wounds account for most penetrating scrotal injuries with stab wounds and human or animal bites also been described in this age group [7]. Thermal and degloving injuries are the rarest cause of scrotal injuries and often require skin grafting [8].

In view of the rare nature of penetrating scrotal injuries and the scarcity of reported cases in Ghana, we did a retrospective review of our records for penetrating scrotal injuries and

present two (2) case reports managed by the urology department at the Cape Coast Teaching Hospital within a 7-year period from 2013-2019 and brief review of literature.

2. CASE REPORTS

2.1 Case Report 1

A healthy 13-year-old male with no medical history presented to the Emergency Department (ED) of Cape Coast Teaching Hospital on 10th September, 2013 with complaint of a stick stuck in his left hemiscrotum and severe pain. He had climbed a coconut tree and accidentally fell from the height and landed on a tree branch in the ground. He suddenly felt an excruciating pain with severity score of 10 and was brought to the ED three (3) hours after the incident. He had no haematuria, abdominal pain, chest pain or abdominal distention.

Patient was haemodynamically stable with BP-110/70mmHg, Pulse-120 bpm, RR-24 cpm, T-36.2 °C, SpO₂-100% on room air. He was not pale, anicteric and not in any obvious respiratory distress. His chest was clinically clear although he had some abrasions on the anterior chest wall. Abdomen was soft, mild tenderness in left groin and no palpable organomegaly. Focused assessment with sonography in trauma (FAST) was negative, no pelvic girdle tenderness.

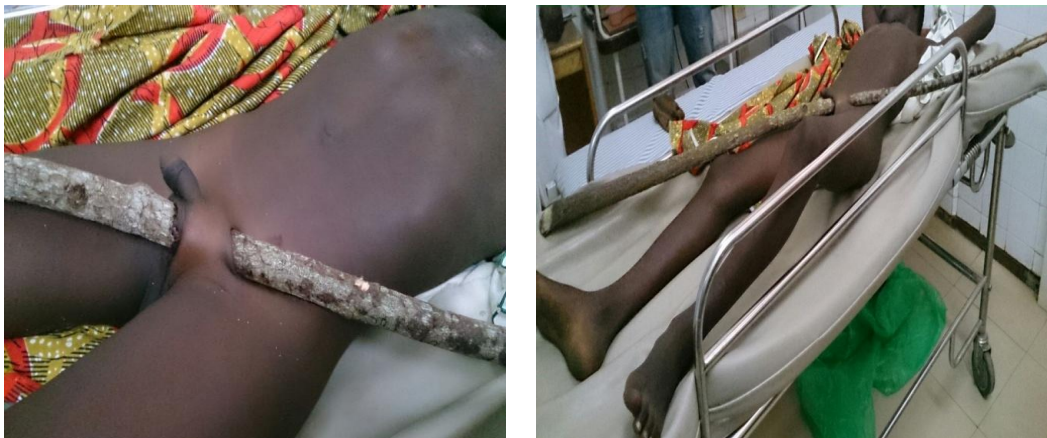

Fig. 1. Patient lying in bed with a long stick in the left hemiscrotum

He had a long stick about 170cm in length pierced through his left hemiscrotum and tender with some blood clot on the stick (Fig. 1). Right testis and hemiscrotum normal. No blood clots or bleeding from tip of penis. Patient was subsequently prepared for emergency scrotal exploration. Complete blood count (CBC), renal function test (RFT) and urinalysis. Investigations were normal.

Intra-operative findings were impalement injury through the left hemiscrotum exiting through the left inguinal region. The scrotal laceration was 4 cm x 3 cm in size (American Association for the Surgery of Trauma (AAST) Grade III). The Left testis and cord were normal. The femoral vessels were not affected. Patient had debridement and primary closure of the scrotal wound. He had an uneventful recovery, administered tetanus toxoid injection and was discharged on Post-operative day 2. Patient at 6 weeks post-operative review also showed uneventful recovery.

2.2 Case Report 2

A healthy 14-year-old male with no medical history presented to the Emergency Department (ED) of Cape Coast Teaching Hospital on 18th November, 2014 after he was pierced in his right hemiscrotum with an iron rod and severe pain. Patient accidentally fell from a height (pawpaw tree) and landed on an iron rod protruding from a nearby wall. He suddenly felt a sharp, excruciating pain with severity score of 10. Patient was pulled off the iron rod and was brought to the ED two (2) hours after the incident.

Patient was haemodynamically stable with BP-110/60mmHg, Pulse-110 bpm, RR-26 cpm, T-36.5°C, SpO₂-100% on room air. He was not pale, afebrile, anicteric and not in any obvious respiratory distress. He had no haematuria, no dyspnea, no abdominal distention but had left-sided abdominal pain. His chest was clinically clear with mild tenderness and subcutaneous emphysema of left anterior chest wall. Patient had a long abrasion tract extending from the left hemithorax, left side of the abdomen, suprapubic region and to the right hemiscrotum. Abdomen was soft, mild tenderness on the left side of the abdomen with subcutaneous emphysema and no palpable organomegaly. No pelvic girdle tenderness. FAST was negative. He had laceration about 2.5 cm x 2.5 cm in size and tender swelling of the right hemiscrotum with exposed testis. No blood clot or bleeding at the tip of the penis.

Patient was subsequently prepared for an emergency scrotal exploration. CBC, RFT and urinalysis were normal. Intra-operative findings were impalement injury of right hemiscrotum exiting through the suprapubic region with exposed normal looking testis and spermatic cord. The laceration was 3 cm x 3 cm in size (AAST II) and had right hemiscrotum haematoma. Patient had debridement and primary closure of the scrotal wound with a right scrotal drain placed in situ. He had an uneventful recovery and scrotal drain was removed on post-operative day 3. Patient also receive tetanus toxoid injection and was discharged on post-operative day 5. Thereafter, at 6 weeks post-operative review, patient also showed uneventful recovery.

3. DISCUSSION

Penetrating scrotal injuries are rare in children and adolescent and most frequently are seen after straddle-type falls or laceration of genital skin due to falls on sharp objects [9,10] as was described in our case reports. Almost all situations of penetrating scrotal injuries (Table 1) require prompt surgical exploration with conservative debridement of non-viable tissue since have a very high rate of associated testicular injury [11]. In both of our cases, the testes were spared any damage. Primary repair of the scrotum are usually performed as was in our cases. However, the repair most often performed depends on the extent of injury [12]. Extensive injury of the tunica albuginea is repaired by mobilization of a free tunica vaginalis flap for testicular closure. In spite of that, in unstable patients, orchiectomy is indicated. Again, in cases of penetrating testicular trauma, the salvage rates are about 50 percent with the remaining patients undergoing orchidectomy [13]. Also, in the case of extensive loss of genital tissue such as in a blast injury, complex and staged reconstructive surgical procedures are often required [14].

Table 1. AAST organ injury severity scale for the scrotum

Grade	Description of injury
I	Contusion
II	Laceration <25% of scrotal diameter
III	Laceration ≥ 25% of scrotal diameter
IV	Avulsion <50%
V	Avulsion ≥ 50%

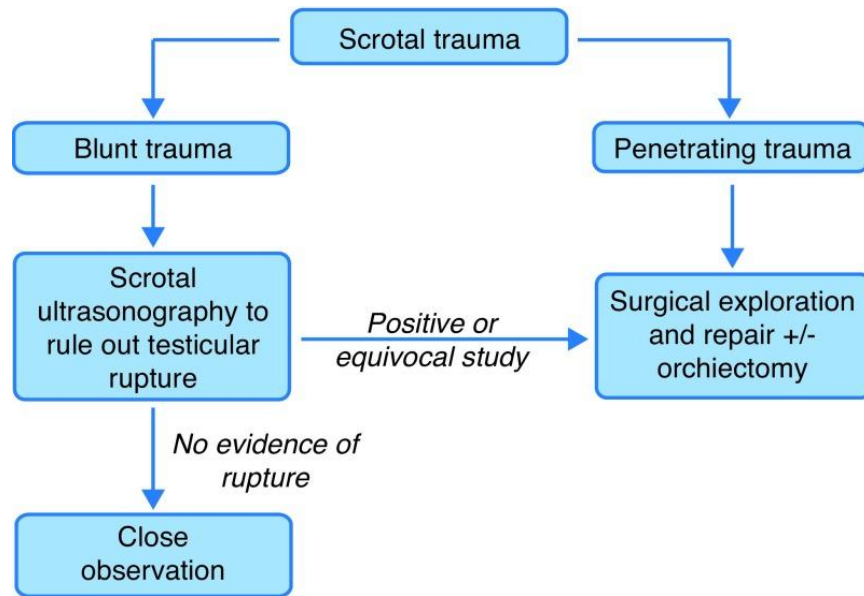


Fig. 2. Simplified diagnostic and management pathway in blunt and penetrating scrotal trauma [15]

Table 2. Scrotal trauma [16]

Condition	Etiology, Presentation	Treatment
Testicular dislocation	Significant blunt-force mechanism (dislocation to the abdomen or to subcutaneous tissues surrounding the external inguinal ring)	Surgical intervention
Testicular rupture	Disruption of the tunica albuginea	Surgical intervention
Testicular contusion	Intratesticular hematoma; intact tunica albuginea	Typically conservative: ice, rest, elevation
Hematocele	Blood accumulation in the tunica vaginalis	Surgical drainage for large hematocele; conservative otherwise
Penetrating injury	Varies depending on cause	Typically surgical exploration/intervention
Traumatic torsion	Traumatically induced torsion has been reported	Typically surgical exploration/intervention

In any penetrating trauma, the tetanus immunization status of the patient has to be determined. According to a recent review, tetanus toxoid booster was recommended in patients with their last immunization given more than 10 years before [17]. This is in contrast to suggestions by the World Health Organization (WHO) recommending tetanus toxoid booster if tetanus immunization was received more than 5 years before in patients with an open wound [18]. Regardless, since toxoid booster does not protect against the current injury, no urgency for the administration of tetanus toxoid in the acute setting has been suggested. However, tetanus

immunoglobulin should be reserved only for previously non-immunized injured patients [17].

In the algorithm (Fig. 2) of managing penetrating scrotal injury, there is no advocate for routine use of preoperative scrotal ultrasonography for penetrating scrotal trauma, therefore there must be a low threshold for early surgical exploration. Most reports have suggested that early exploration leads to higher testicular salvage rates compared with late exploration [19,20] which invariably helps to maintain endocrine function and provide psychological benefit of preserving the native testis [11,21]. It is

imperative to explore all injuries that have penetrated or are suspected to have penetrated dartos of the scrotum [7].

However, blunt trauma to the scrotum can cause testicular dislocation, testicular haematocoele, testicular rupture, traumatic testicular torsion, testicular contusion and scrotal haematoma [22,23] where ultrasound evaluation is useful in determining the type and degree of injury present. Some even suggest the use of contrast enhanced ultrasound (CEUS) in children to evaluate blunt scrotal injuries and have been found to be safe, feasible, diagnostically robust and effective [24]. The different types injuries that may be encountered in scrotal trauma, presentation and possible intervention required are summarized in Table 2. Among them, testicular rupture is found in approximately 50% of cases of direct blunt scrotal trauma [25]. Interestingly, most patients do well post operatively from scrotal trauma with a reported relatively low complication ranging from 2 to 7.7% among series at level I trauma centers [7,13]. Complications reported include abscess and hematoma formation which can be managed with drainage or evacuation [26].

4. CONCLUSION

Penetrating scrotal trauma may spare the testis and the scrotal contents despite the gravity of the injury. However, urgent scrotal exploration is required.

CONSENT

As per international standard or university standard written patient consents have been collected and preserved by the author(s).

ETHICAL APPROVAL

As per international standard or university standard written ethical approval has been collected and preserved by the author(s).

COMPETING INTERESTS

Authors have declared that no competing interests exist.

REFERENCES

1. Prajapati DK, Rampal K, Prajapati JM, Review of diagnosis and management of scrotal trauma with a case report. *Int J Med Res Prof.* 2016;2(3):197-200. DOI: 10.4103/UA.UA_69_17 [PubMed]
2. Buckley JC, McAninch JW. Use of ultrasonography for the diagnosis of testicular injuries in blunt scrotal trauma. *J Urol.* 2006;175:175-178. DOI: 10.1016/S0022-5347(05)00048-0
3. Widni EE, Höllwarth ME, Saxena AK. Analysis of nonsexual injuries of the male genitals in children and adolescents. *Acta Paediatr.* 2011;100:590. DOI: 10.1111/j.1651-2227.2010.02088.x [PubMed]
4. Sung EK, Setty BN, Castro-Aragon I. Sonography of the pediatric scrotum: emphasis on the Ts-torsion, trauma, and tumors. *AJR Am J Roentgenol.* 2012;198:996. DOI: 10.2214/AJR.11.8034 [PubMed]
5. Bertozzi M, Prestipino M, Nardi N, Falcone F, Appignani A. Scrotal dog bite: Unusual case and review of pediatric literature. *Urology* 2009;74:595. DOI: 10.1016/j.urology.2009.02.056 [PubMed]
6. O'Brien M, Hutton KA. Minimally invasive retrieval of a foreign body after penetrating soft tissue injury. *J Trauma.* 2005;59:754. [PubMed]
7. Phonsombat S, Master VA, McAninch JW. Penetrating external genital trauma: A 30-year single institution experience. *J Urol.* 2008;180:192. DOI: 10.1016/j.juro.2008.03.041 [PubMed]
8. Deurdulian C, Mittelstaedt CA, Chong WK, Fielding JR. US of acute scrotal trauma: Optimal technique, imaging findings, and management. *Radio Graphics.* 2007;27:357-369. DOI: 10.1148/rg.272065117 [PubMed]
9. Monga M, Hellstrom WJ. Testicular trauma. *Adolesc Med.* 1996;7:141. [PubMed]
10. Okur H, Kucikaydin M, Kazez A, Turan C, Bozkurt A. Genitourinary tract injuries in girls. *Br J Urol.* 1996;78:446. [PubMed].
11. Morey AF, Metro MJ, Carney KJ, Miller KS, McAninch JW. Consensus on genitourinary trauma: External genitalia. *BJU Int.* 2004; 94:507-515. DOI: 10.1111/j.1464-410X.2004.04993.x [PubMed]
12. Altarac S. A case of testicle replantation. *J Urol.* 1993;150(5 Pt 1):1507-8. DOI: 10.1016/s0022-5347(17)35828-7 [PubMed]

13. Simhan J, Rothman J, Canter D, Reyes JM, Jaffe WI, Pontari MA, et al. Gunshot wounds to the scrotum: a large single institutional 20-year experience. *BJU Int.* 2012;109:1704.
DOI: 10.1111/j.1464-410X.2011.10631.x [PubMed]
14. Hudak SJ, Hakim S. Operative management of wartime genitourinary injuries at Balad Air Force Theater Hospital, 2005 to 2008. *J Urol.* 2009; 182(1):180-3.
DOI: 10.1016/j.juro.2009.02.150 [PubMed]
15. Randhawa H, Blankstein U, Davies T. Scrotal trauma: A case report and review of the literature. *Can Urol Assoc J.* 2019; 13(6 Suppl4):S67-71.
DOI: 10.5489/cuaj.5981 [PubMed]
16. Davis JE, Silverman M. Scrotal emergencies. *Emerg Med Clin N Am.* 2011;29:469-484.
DOI: 10.1016/j.emc.2011.04.011 [PubMed]
17. Rhee P, Nunley MK, Demetriades D, Velmahos G, Doucet JJ. Tetanus and trauma: A review and recommendations. *J Trauma.* 2005;58:1082.
DOI: 10.1097/01.ta.0000162148.03280.02 [PubMed]
18. World Health Organization (2000) Fact sheet No. 241; 2000.
19. Brandes SB, Buckman RF, Chelsky MJ, Hanno PM. External genitalia gunshot wounds: a ten-year experience with fifty-six cases. *J Trauma.* 1995;39:266-271.
DOI: 10.1097/00005373-199508000-00013 [PubMed]
20. Cass AS, Ferrara L, Wolpert J, Lee J. Bilateral testicular injury from external trauma. *J Urol.* 1988;140:1435-1436.
DOI: 10.1016/s0022-5347(17)42066-0 [PubMed]
21. Bandi G, Santucci RA. Controversies in the management of male external genitourinary trauma. *J Trauma.* 2004;56:1362-1370.
DOI: 10.1097/01.ta.0000119197.56578.e2 [PubMed]
22. Summertom DJ, Djakovic N, Kitrey ND, Kuehhas F, Lumen N, Serafetinidis E, et al. Guideline on urological trauma. *European Association of Urology.* 2013;41-42.
23. Papoutsoglou N, Thiruchelvam N. Diagnosis and management of testicular injuries. *Med Surg Urol.* 2013;2:2.
DOI: 10.4172/2168-9857.1000108 [PubMed]
24. Rosado E, Riccabona M. Off-label use of ultrasound contrast agents for intravenous applications in children: analysis of the existing literature. *J Ultrasound Med.* 2016; 35:487-496. [PubMed]
25. Cass AS, Luxenberg M. Testicular injuries. *Urology.* 1991;37(6):528-30.
DOI: 10.1016/0090-4295(91)80317-z [PubMed]
26. Jensen D, Patel MS, Culp SH. Penetrating scrotal trauma: A case report and brief management with literature review. *J Trauma Treat.* 2014;3:3.
DOI: 10.4172/2167-1222.1000205 [PubMed]

© 2020 Ofori et al.; This is an Open Access article distributed under the terms of the Creative Commons Attribution License (<http://creativecommons.org/licenses/by/4.0>), which permits unrestricted use, distribution, and reproduction in any medium, provided the original work is properly cited.

Peer-review history:

The peer review history for this paper can be accessed here:
<http://www.sdiarticle4.com/review-history/57863>